

QUIZ 1

Bahram Azadeh MD FRCPATH
Hamad Medical Corporation

This 32-year-old Egyptian man had a “swelling” (of unspecified duration) in front of his right knee for which he was referred to a general surgeon. A subcutaneous mass from the upper anterior tibial region was resected. The specimen submitted was a pale gray relatively well circumscribed ovoid lump (25 x 12 x 7 mm) with a rubbery consistency and a pale gray solid cut surface.

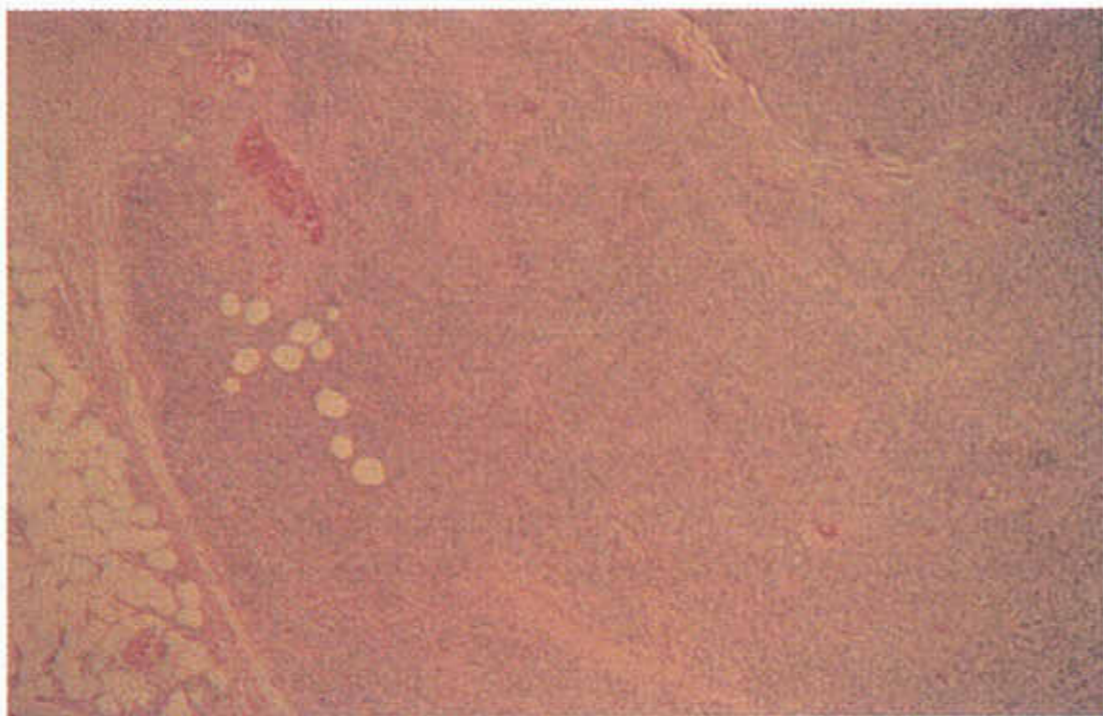


Fig. 1: H&E x 8

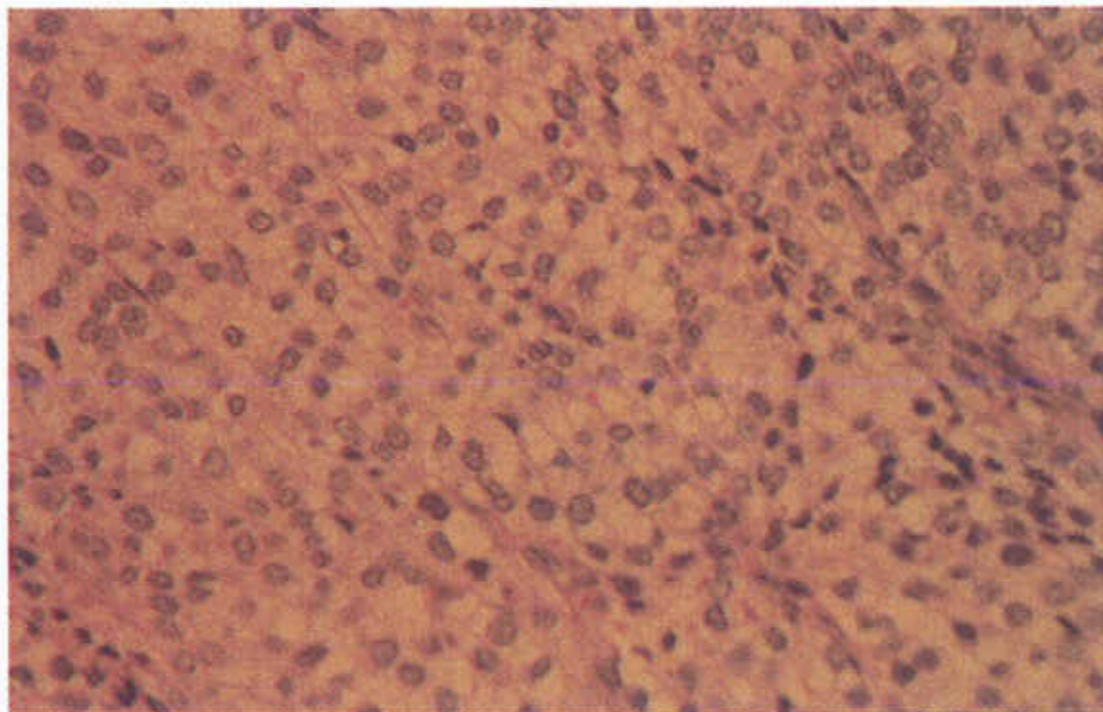


Fig. 2: H&E x 50

What is your diagnosis?

Correspondence:
Bahram Azadeh MD FRCPATH
Hamad Medical Corporation
P O Box 3050, Doha, Qatar

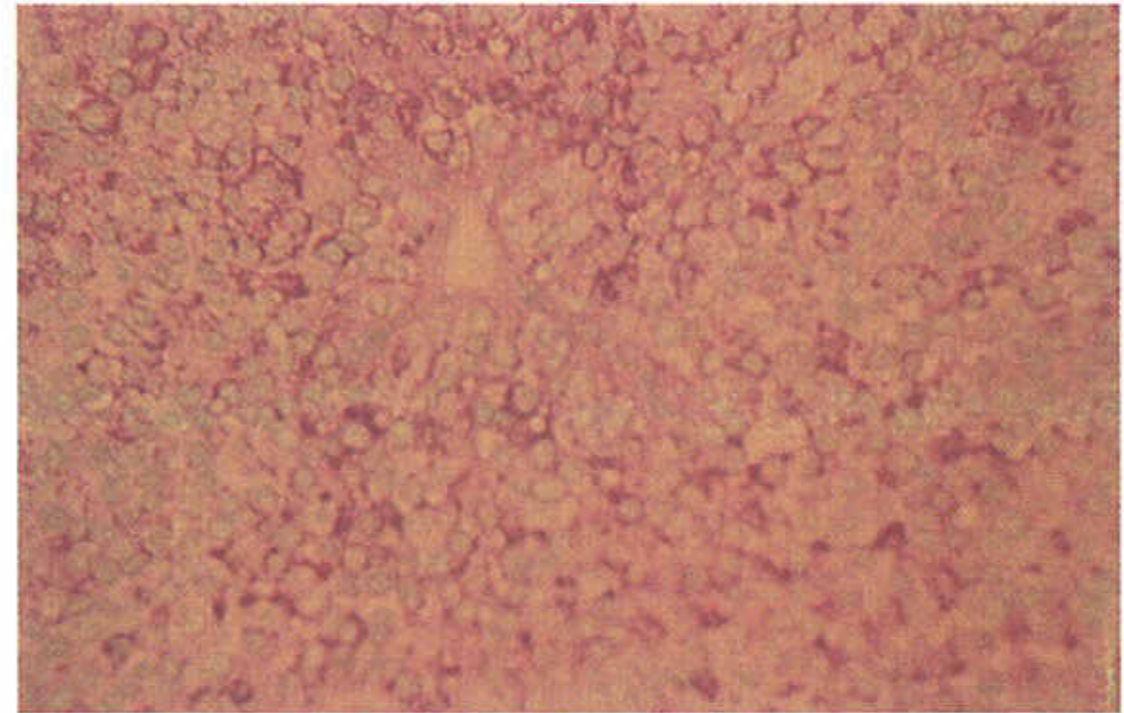


Fig. 3: PAS x 50

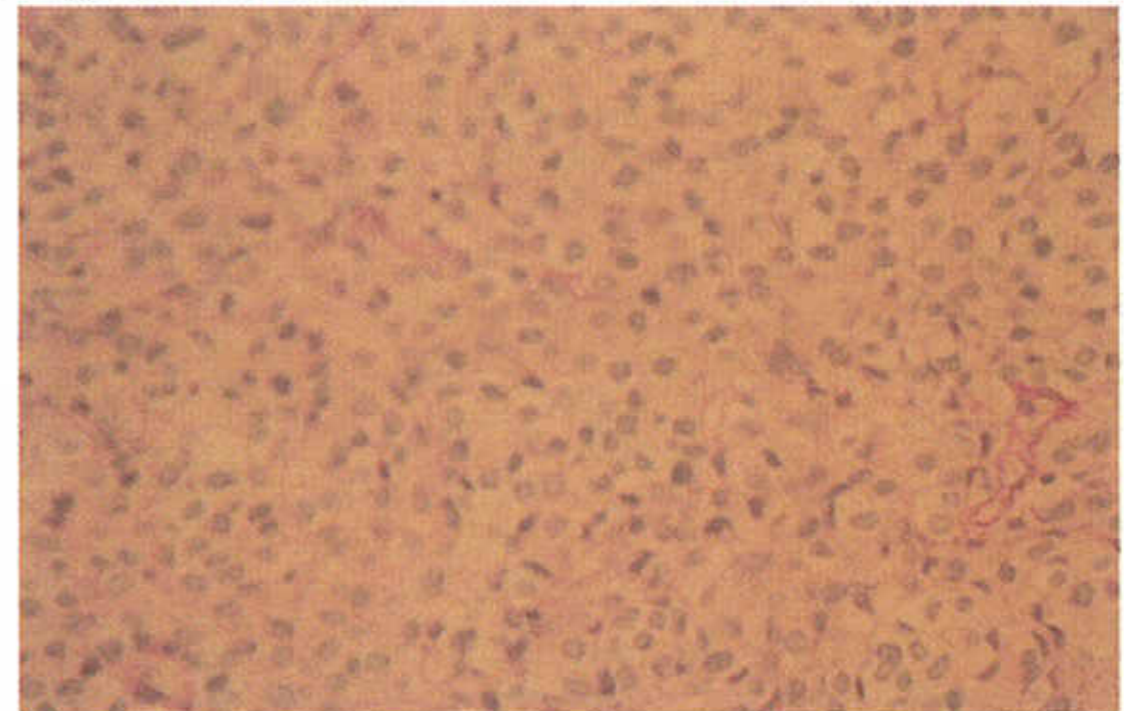


Fig. 4: PAS after diastase digestion x 50

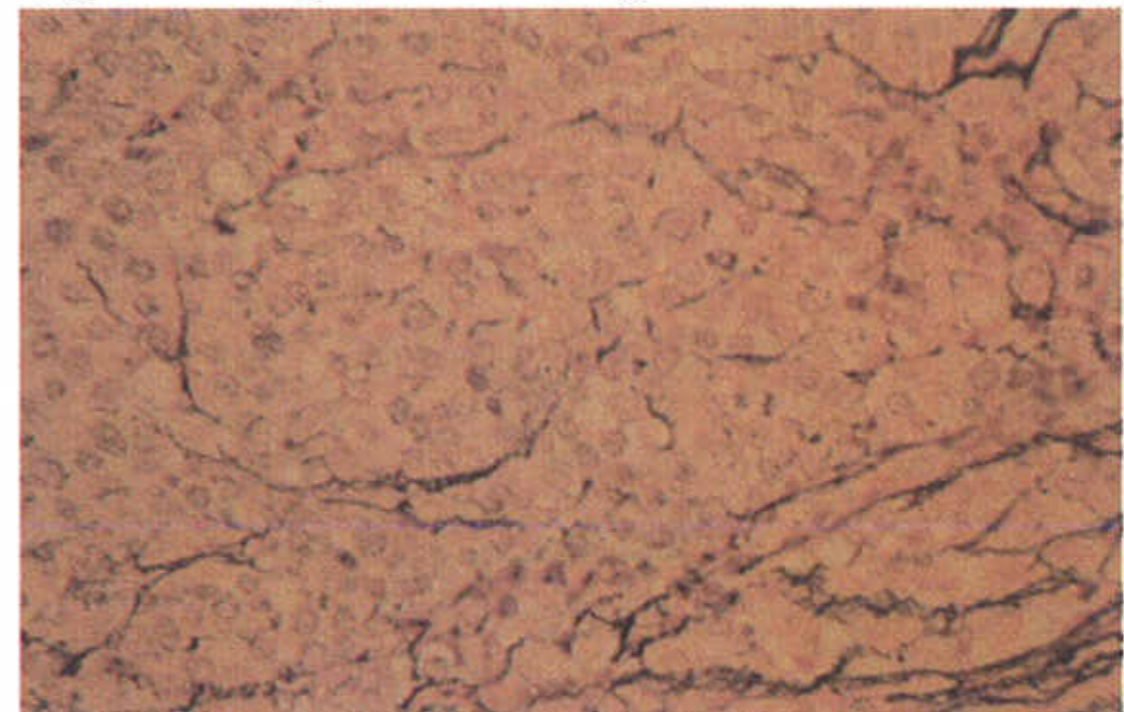


Fig. 5: Reticulin stain x50

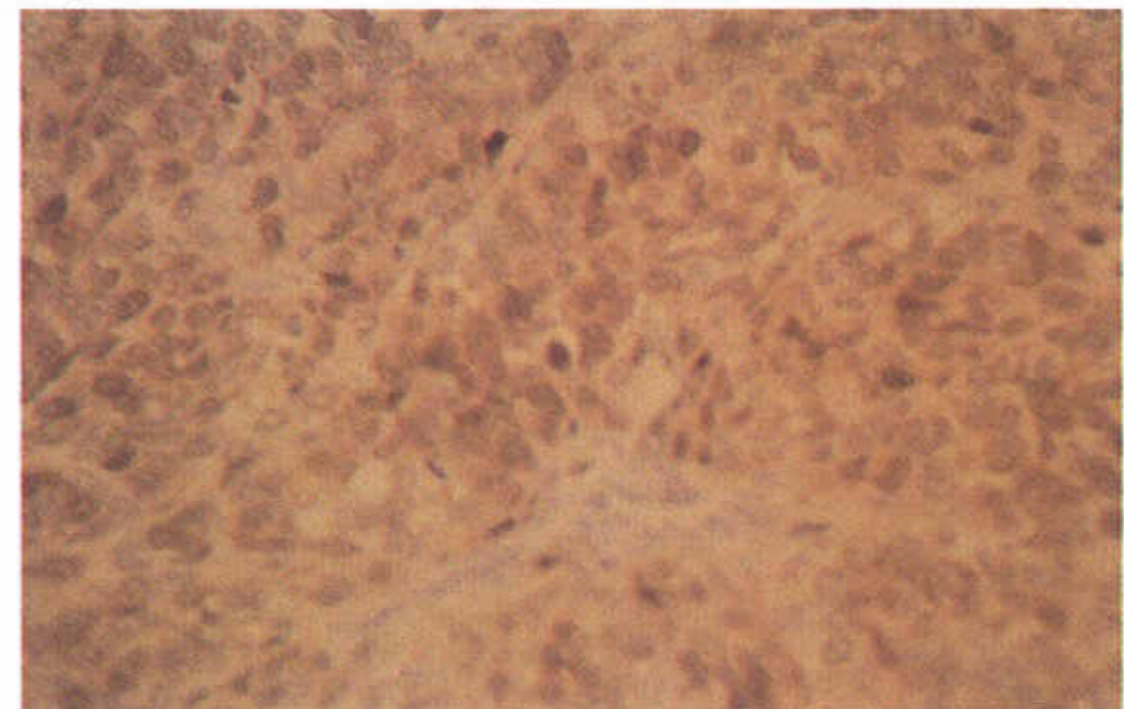


Fig. 6: Immunoperoxidase staining for S-100 protein

QUIZ 2

Bahram Azadeh MD FRCPATH
Hamad Medical Corporation

This 32-year-old Palestinian man had a subcutaneous lesion resected from upper part of his forehead, presumed to be a “sebaceous” cyst. Four months earlier a lesion had been resected from the same site in another hospital (no slide or report was available)

The specimen submitted was gray tan in colour and measured 12 x 6 x 4 mm.

Figures 1-4 are from H&E stained sections of this subcutaneous lesion.

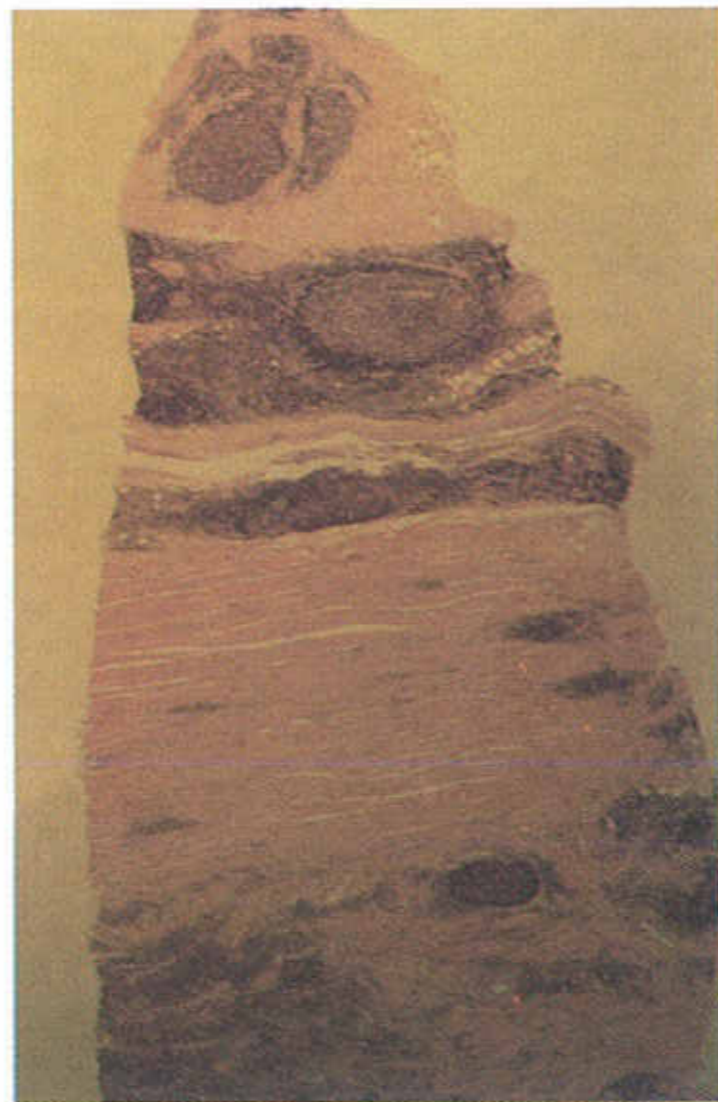


Fig. 1: H&E x 8

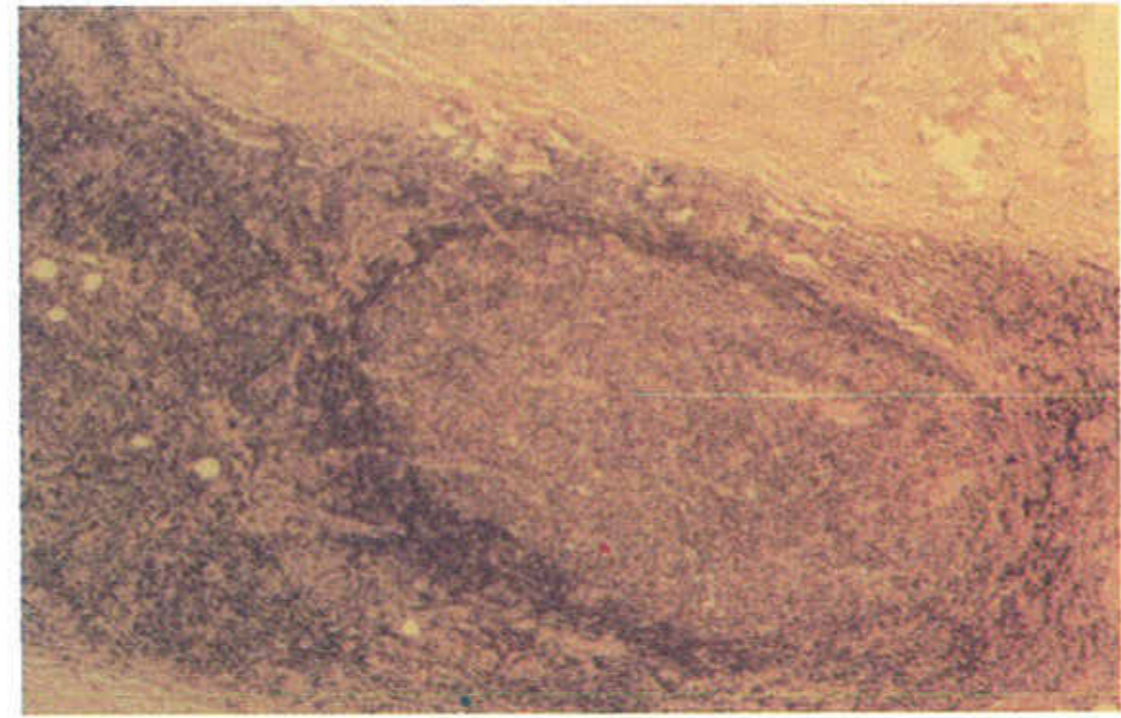


Fig. 2: PAS x 50

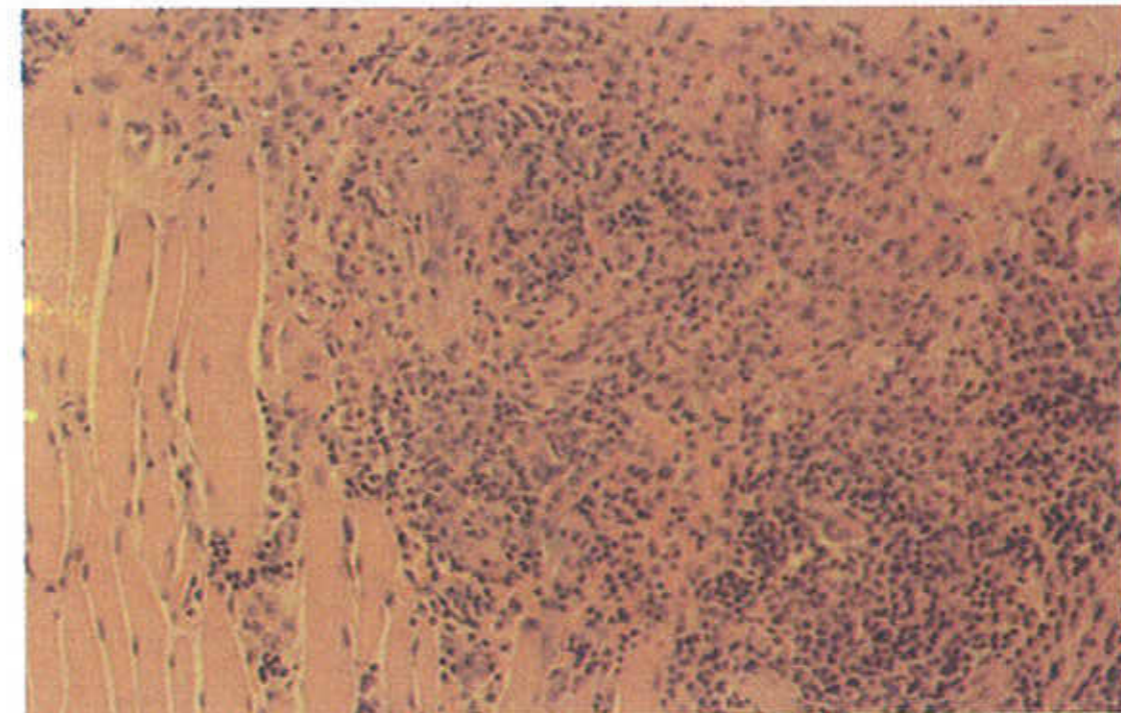


Fig. 3: PAS after diastase digestion x 50

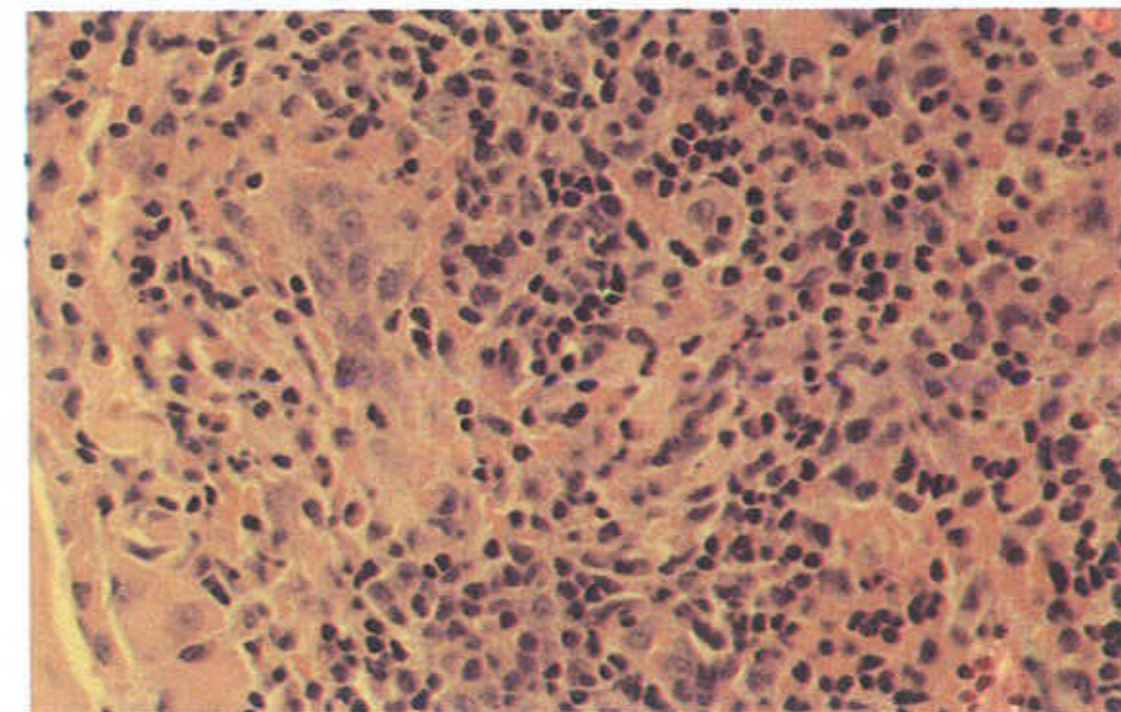


Fig. 4: Reticulin stain x50

What is your diagnosis?

QUIZ 3

Bahram Azadeh MD FRCPATH
Hamad Medical Corporation

A 47-year-old Qatari woman had a lump in her left thigh of two years duration, recently increased in size. It was resected in the day care unit. The specimen consisted of skin 30 x 18 mm over grayish white firm tissue to the depth of 17 mm.

Figures 1-4 are from H&E stained sections of the lesion. What is your diagnosis?

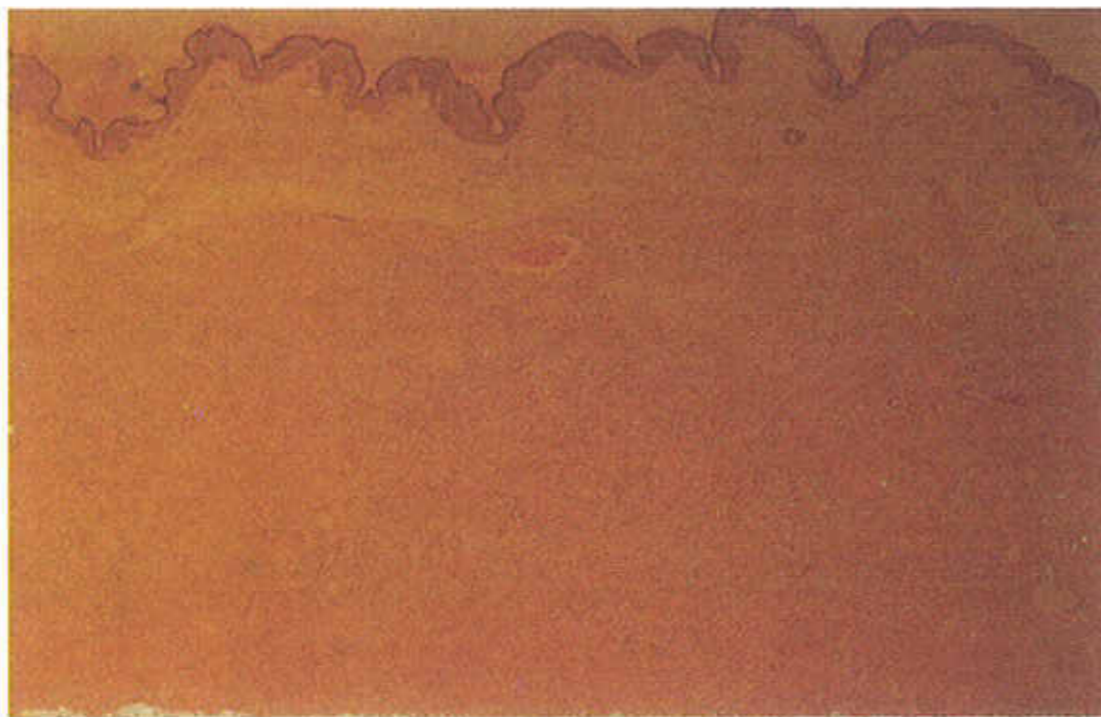


Fig. 1: H&E x 8



Fig. 2: PAS x 50

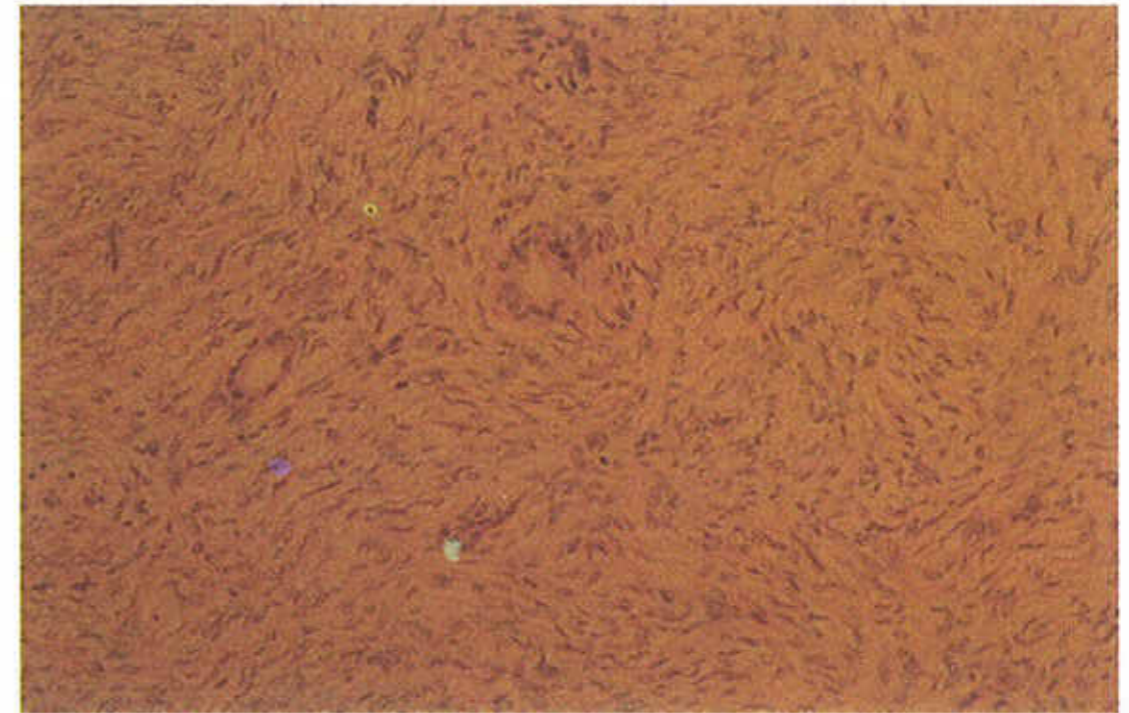


Fig. 3: PAS after diastase digestion x 50

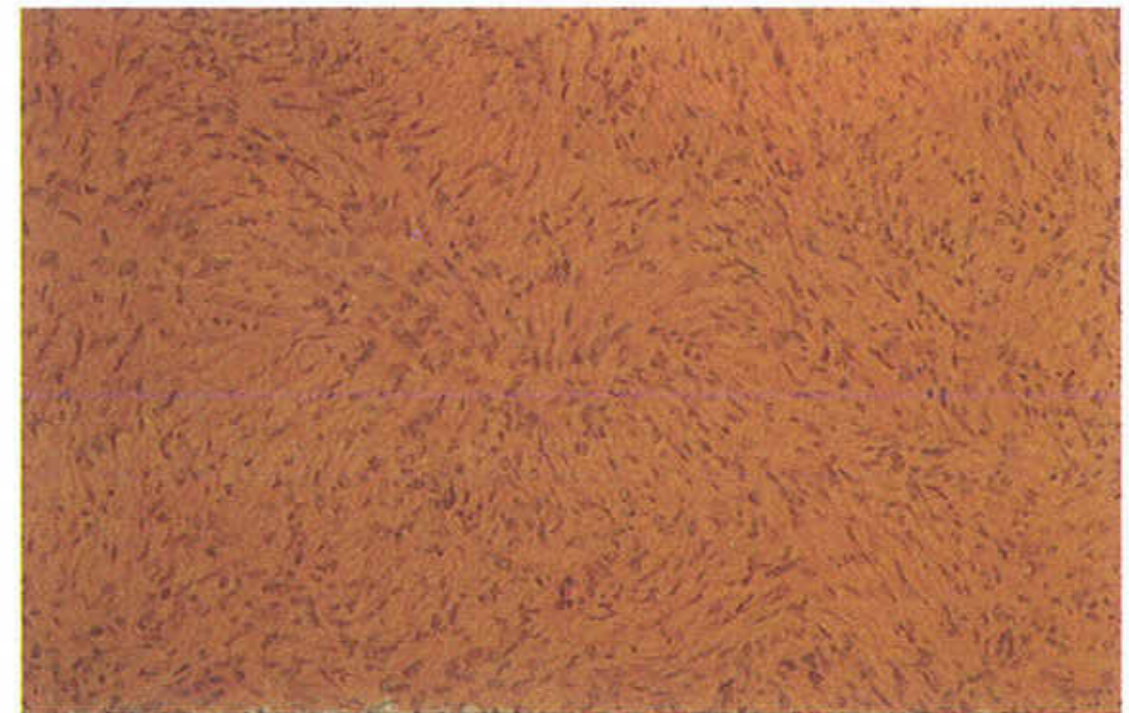


Fig. 4: Reticulin stain x50

What is your diagnosis?