

QUIZ 3

Bahram Azadeh, MD, FRCPath*
Ahmed Hazim Takiddin, MBBS, HSC
Mohammed Mohy El-Din Selim, MD

Departments of Pathology* and Dermatology,
Hamad Medical Corporation, P.O. Box 3050,
Doha, Qatar.

Answer on page 54

Answer on additional figures 5 to 12

QUIZ 3.

Figures 1 to 4 illustrate hematoxylin and eosin stained sections of a skin lesion, in the anterior aspect of the chest wall of a 35-year-old Indian man.

WHAT IS YOUR DIAGNOSIS?

Staining Technique

Fig 1 - 4: H&E (Haematoxylin & Eosin) stain

Fig 5 - 8: Iron Stain "Perls' stain"

Fig 9 -11: H & E

Fig 12: Perls' stain

Fig 5: Low power Perls' stain

Fig 6: Coarse and fine iron pigments especially in giant cells

Fig 7: Coarse iron pigment deposition in giant cells and surrounding connective tissue

Fig 8: Ferrogenation of connective tissue fibers, Perls' stain

Fig 9: Lower power } Epithelioid granuloma with a mantel

Fig 10: Medium power } of dense lymphocytic infiltrate

Fig 11: High power }

Fig 12: First biopsy as shown in Fig 9 - 11. Note the absence of any iron pigment

Fig.2

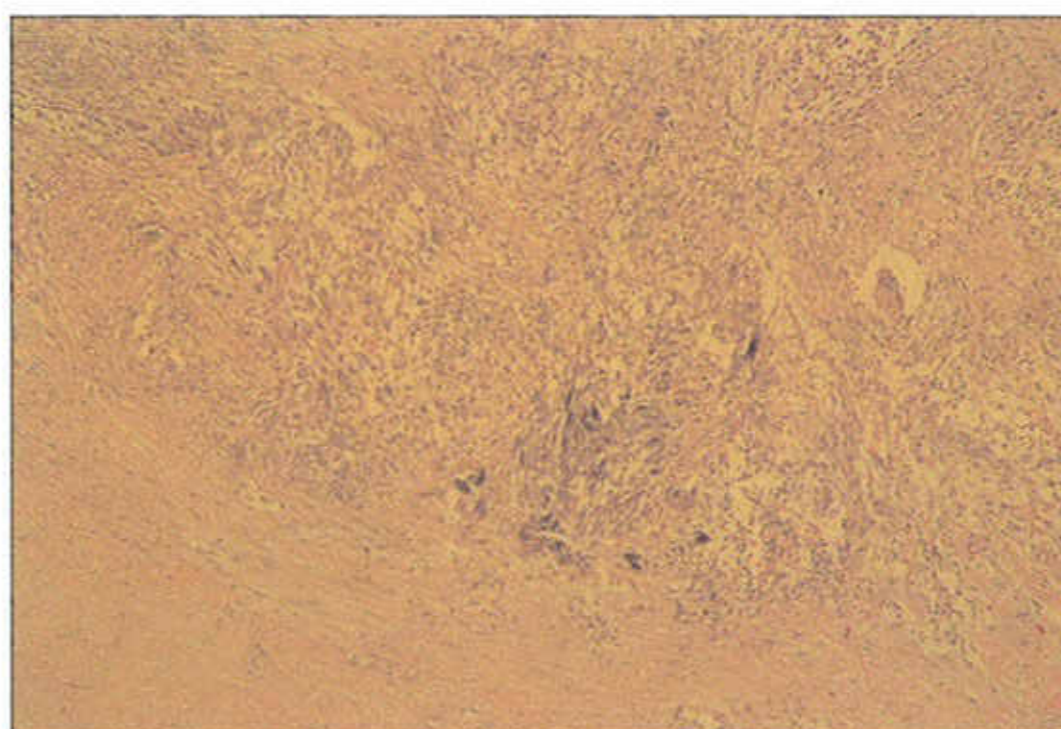


Fig.3

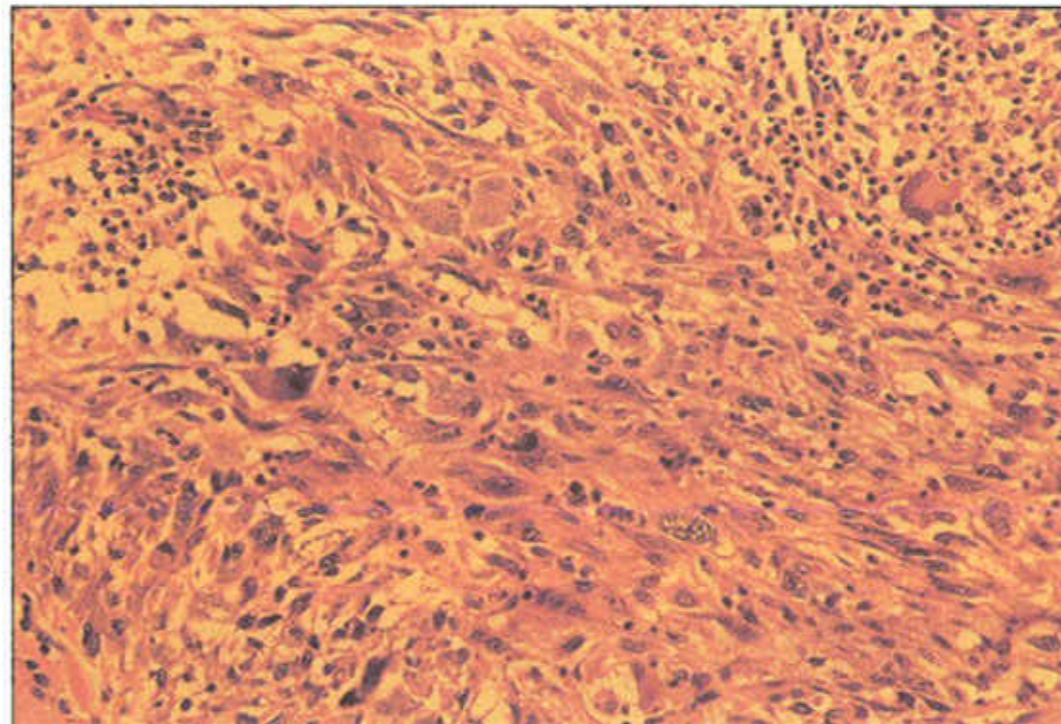


Fig.4

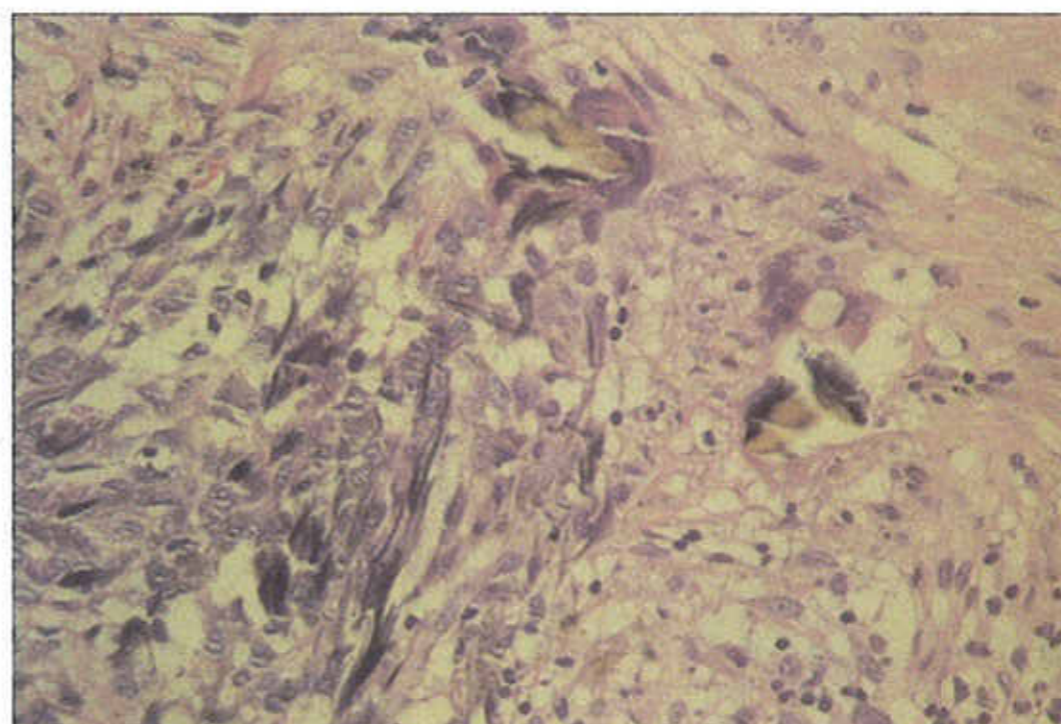


Fig.1

