

QUIZ 2

Bahram Azadeh, MD FRCPATH,

Osama T El-Bakri, FRCSI*

Nina Boghoumian, MD

Departments of Pathology and ENT*,
Hamad Medical Corporation, P.O. Box 3050, Doha, State of Qatar.

QUIZ 2.

Figures 1 to 4 illustrate hematoxylin and eosin-stained sections of an ulcerated nasal polyp from a 32-year-old Indian man.

What is your diagnosis?

Answer on page 53

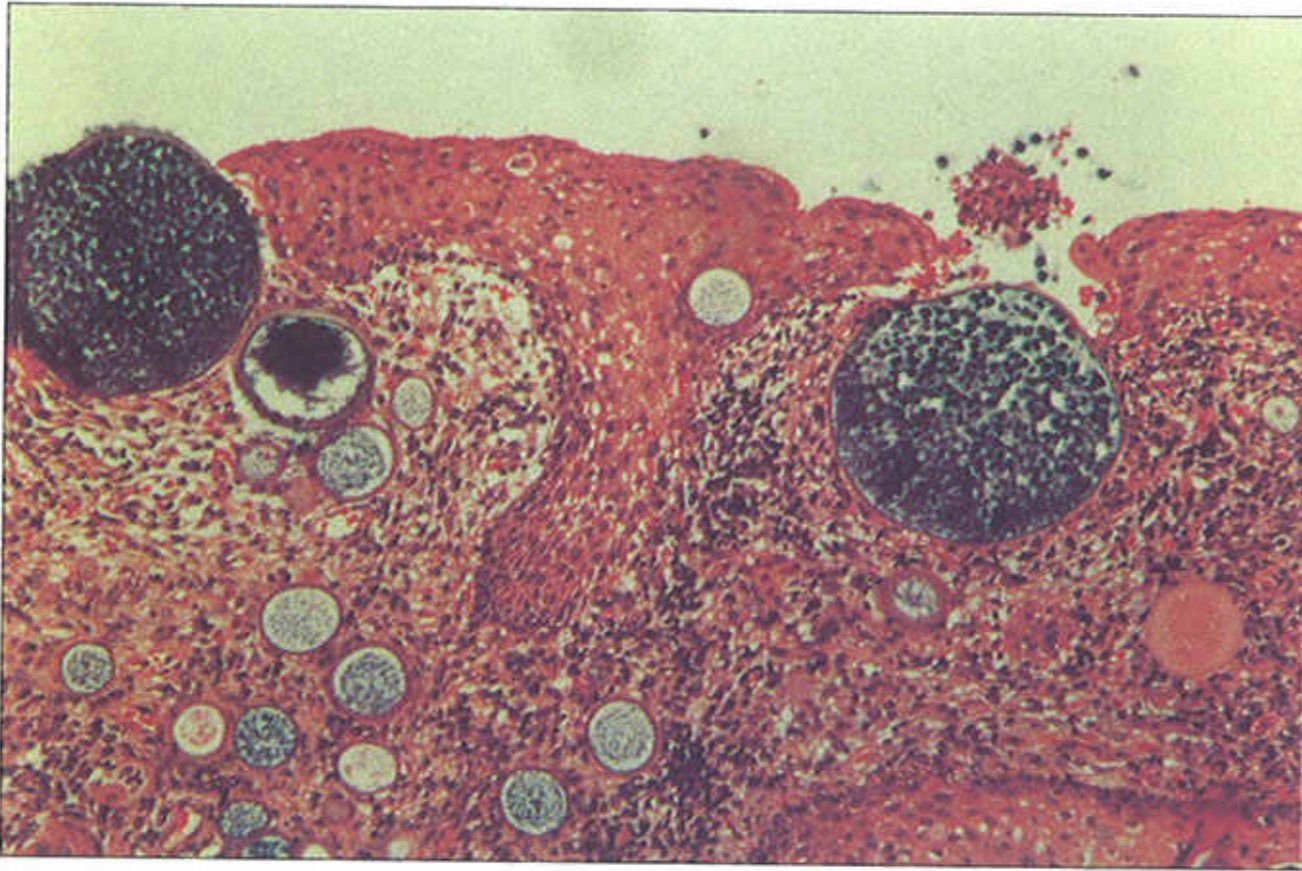

Fig. 1

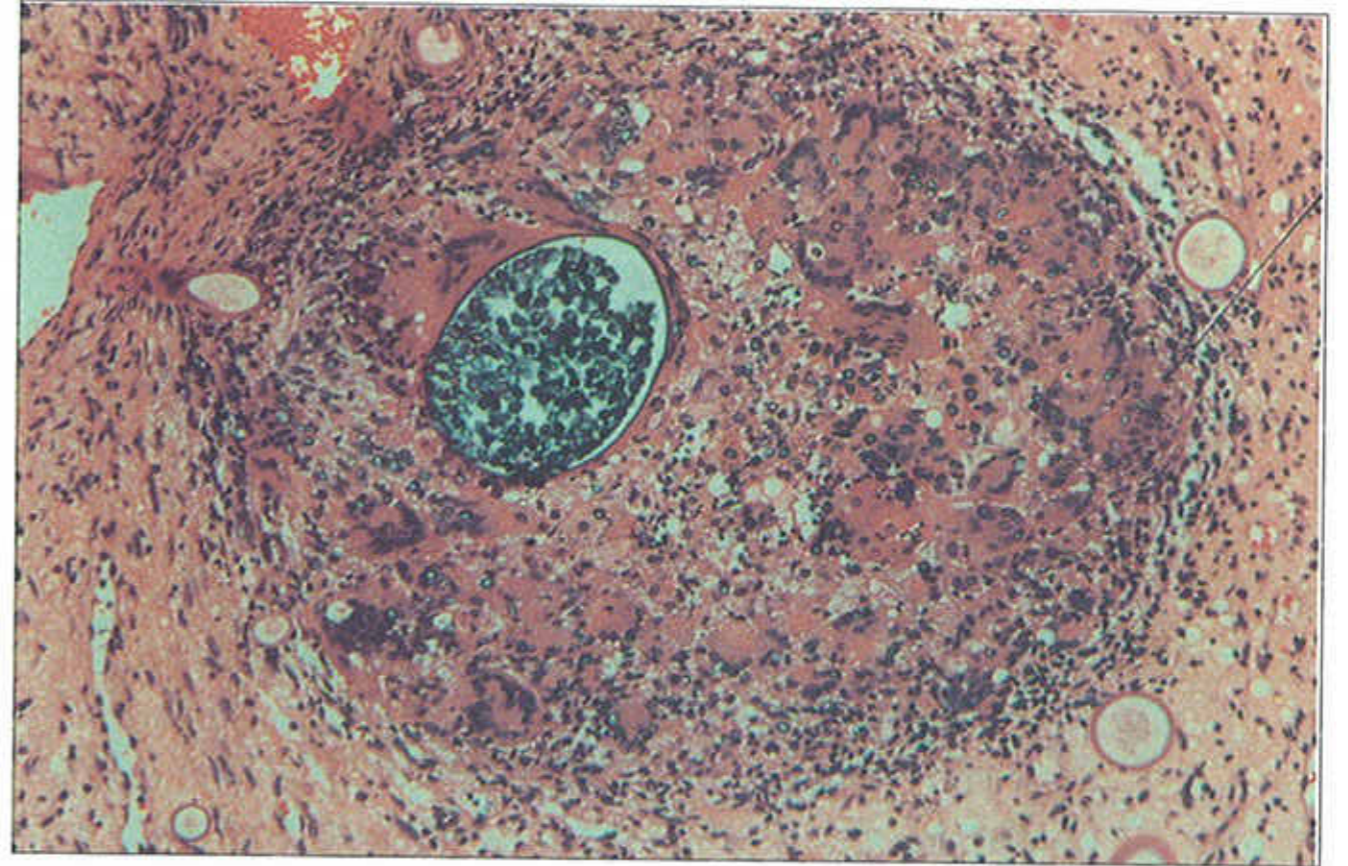


Fig. 3

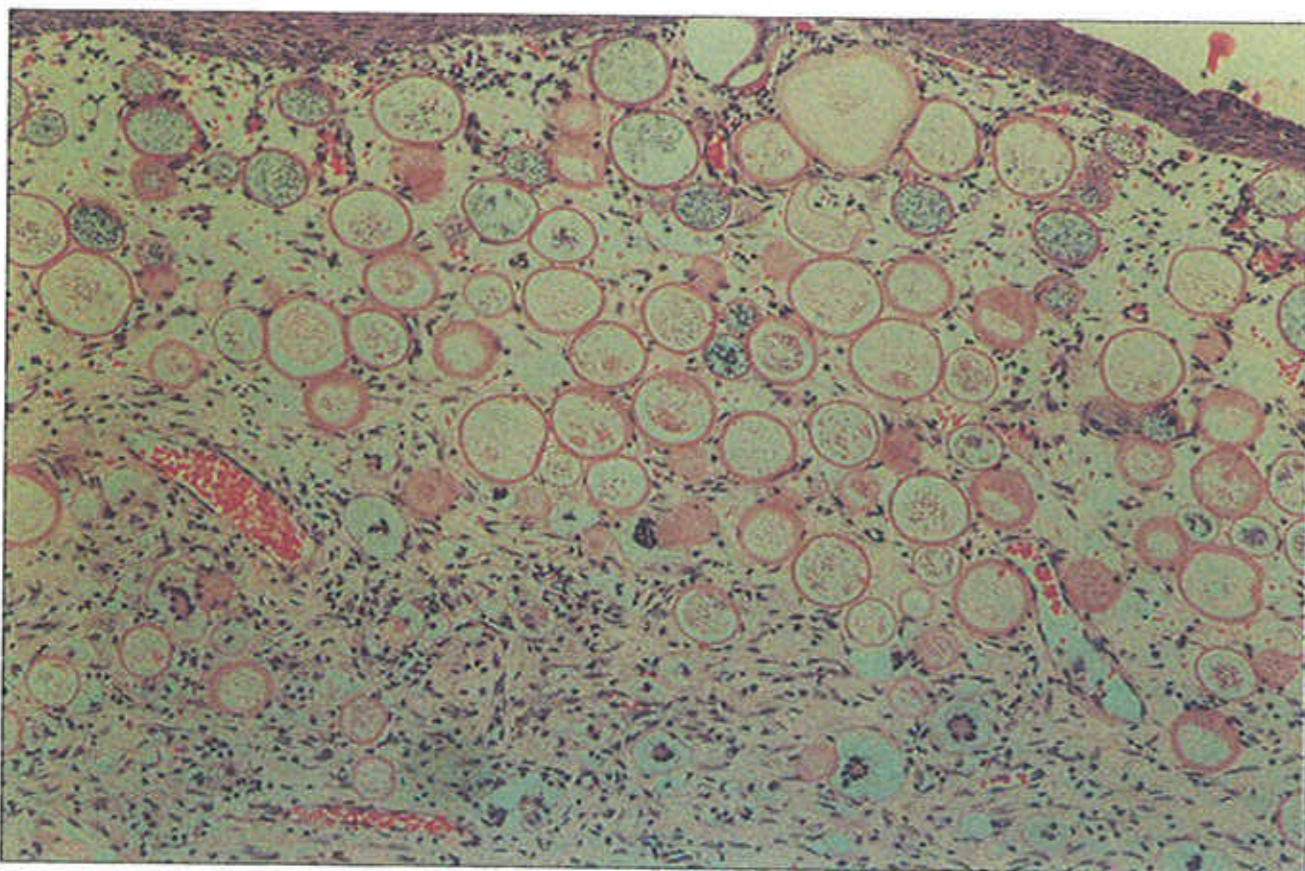


Fig. 2

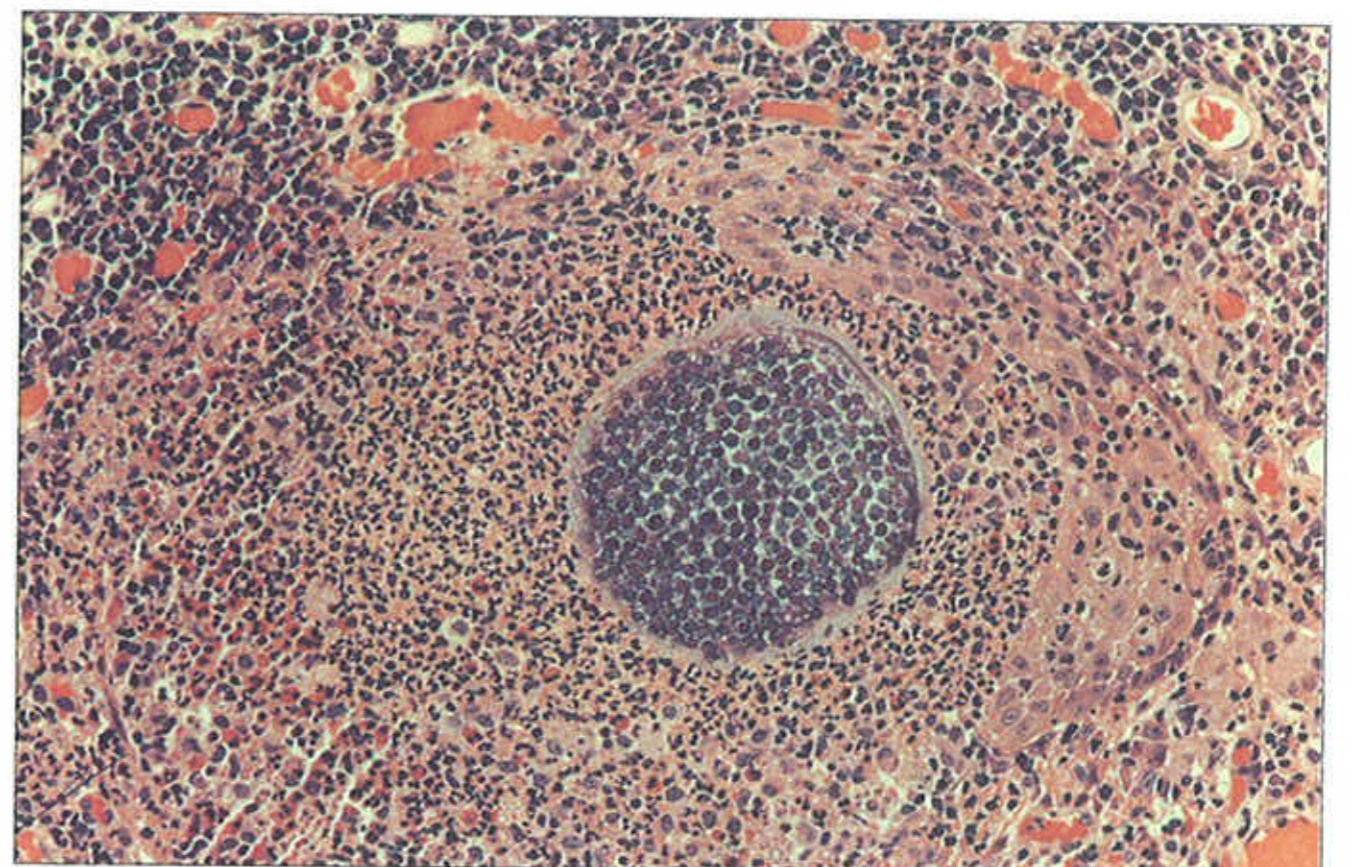


Fig. 4